

# A Novel Reparative and Reconstructive Procedure for Knee Patellofemoral Joint Chondral-Osteochondral Defects

Derek Dee, MD, Michelle H. McGarry, MS, Erika Augenstein, BS, Thay Q Lee, PhD,  
*Investigation performed at Robotics Surgery Center, Los Angeles, California, United States*

## BACKGROUND

Chondral and osteochondral defects of the patellofemoral joint (PFJ) are a common problem in the general population as well as in athletes. The treatment of PFJ chondral and osteochondral defects is challenging due to many intrinsic and extrinsic factors. Factors that contribute to treatment challenges include variation in anatomy, patella cartilage thickness, high joint reaction and shear forces, concomitant instability and malalignment, the relative uncontained nature of the patella, and the relative hardness of patella bone versus trochlea bone. Subchondral bone has been shown to be a source of pain and a key element in the progression of arthrosis. Sequelae include bone hypertrophy and intralesional osteophytes, bone edema, incomplete trabecular incorporation, cystic changes, trabecular fractures and sclerosis, progressive arthroses, and persistent pain. To date, treatments for osteochondral defects have focused on reparative techniques to restore surface anatomy, or reconstructive techniques. Little has been done to address the subchondral bone which functions as the foundation of the osteochondral unit.

## OBJECTIVES

To describe a single-stage reparative and reconstructive technique using an HA-coated titanium implant for patellofemoral osteochondral defects and disease, and to report the early radiographic and clinical outcomes.

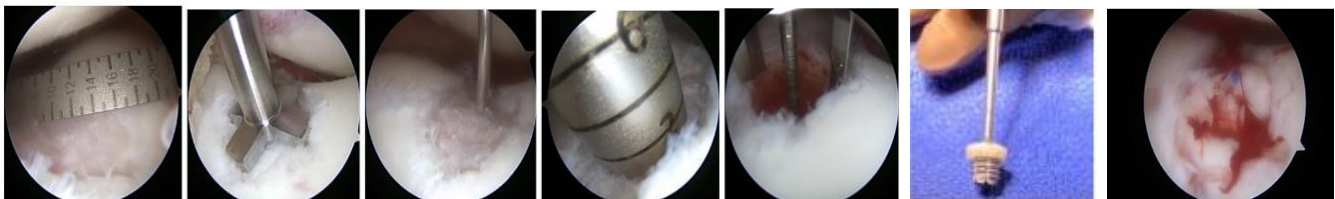
## METHODS

Fourteen consecutive patients from June 2020 to Jan 2022 were included in the study. With Informed consent, clinical data was obtained for clinical improvement purposes. The inclusion criteria were a Kellgren-Lawrence score of 1-2, Outerbridge score of III/IV, anterior knee pain and/or mechanical symptoms, and at least one category from the Osteochondral Fracture-Damage Score on XR, MRI, CT, or bone scintigraphy.

### Osteochondral Fracture-Damage Score (1 point for each, additive, total 8)

- a) Bone Hypertrophy (1 point)
  - i) Upward Migration Subchondral bone plate (XR, T1)
  - ii) Intralesional Osteophytes (XR, T1)
  - iii) Sclerosis
- b) Bone Cysts (1 point)
- c) Bone Edema T2/STIR (1-2 points)
  - i) < 5mm depth
  - ii) > 5mm depth
- d) Bone fracture defect/osteochondrosis, T1 changes (1-2 points)
  - i) > 5mm depth
  - ii) > 5mm depth

All trochlear defects were treated arthroscopically with a cannulated HA-coated titanium implant. Patellar defects were treated with a mini-open incision with partial eversion of the patella. The reparative portion of the procedure involved the following steps: 1. A guide pin was placed in the center of the defect; 2. A countersink preparation reamer was used to remove the superficial 2-3mm of diseased subchondral bone; 3. A coring reamer was used to create a circular osteotomy



to decompress the bone, create a bleeding channel, and a space for the implant; 4. The HA-coated implant was inserted over the guide-wire to the correct depth, countersunk in the subchondral bone. The implant sizes ranged from 4-10mm in diameter. In all procedures except one, a 3-3.5mm thick acellular dermal allograft was used to complete the reconstruction. All grafts were sized to their respective implant size. Fenestrations in the titanium implant were used as fixation points for the graft.

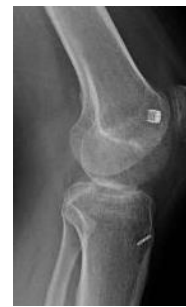Radiographs and Patient reported outcome (PRO) scores including Pain, KOOS, IKDC Subjective, Lysholm and Tegner were collected at baseline, 3 months, 6 months, 1 year and 2 years. Post-operative regimen consisted of immediate unrestricted ROM, CPM, protected WBAT in brace locked in extension for 4 wks.

## RESULTS

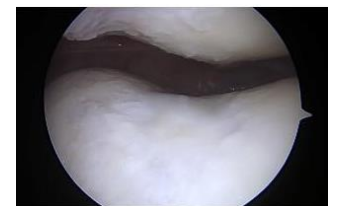Fourteen patients, fifteen knees (10 male and 4 female, ages 27-63 years (mean 50 years)) were included. Mean follow up was 14.1 months (6-24 months). All patients achieved radiographic osseous union of the implant, without cystic changes, sclerotic lines, or signs of implant migration, loosening, or subsidence. There were no failures due to graft dislodgement or need for further surgery. Specifically, all patients demonstrated acceptable early radiographic, clinical and functional scores, and pain relief at most recent follow-up. There was a significant improvement in PRO scores for all categories ( $P < 0.001$  for each parameter) (Table 1) as well as improved scores versus historical controls such as microfracture, OAT, OCA, and other reparative techniques (Table 2).

**Table 1. Patient Reported Outcomes for Current Study**  
Values shown as Mean  $\pm$  Standard deviation.

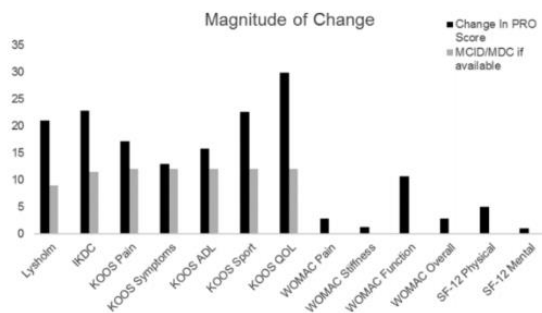
	Pre-Op Score	Last Follow-up	Improvement
Pain Score	7.1 $\pm$ 2.4	1.1 $\pm$ 1.5	-6.0 $\pm$ 2.9
KOOS-Total	35.9 $\pm$ 16.7	86.5 $\pm$ 14.6	50.6 $\pm$ 28.3
KOOS-Pain	48.4 $\pm$ 23.0	91.4 $\pm$ 11.6	42.9 $\pm$ 29.1
KOOS-Symptoms	46.7 $\pm$ 18.7	92.4 $\pm$ 11.1	45.6 $\pm$ 26.2
KOOS-ADL	49.7 $\pm$ 25.3	94.2 $\pm$ 9.3	44.5 $\pm$ 30.4
KOOS-Sports	12.1 $\pm$ 14.5	81.8 $\pm$ 23.2	69.6 $\pm$ 31.5
KOOS-Quality of Life	22.3 $\pm$ 19.4	72.9 $\pm$ 23.8	50.6 $\pm$ 39.1
IKDC	27.9 $\pm$ 12.6	77.6 $\pm$ 14.4	49.7 $\pm$ 21.0
Lysholm	44.9 $\pm$ 23.0	91.0 $\pm$ 12.4	46.1 $\pm$ 28.5
Tegner	2.1 $\pm$ 1.5	4.4 $\pm$ 2.2	2.3 $\pm$ 1.6



Post-op Xray



Arthroscopic 2<sup>nd</sup> Look



From: Weber et al. Clinical outcomes after microfracture of the knee. OJSM 2018: 1-7

Table 2. Patient reported outcomes for osteochondral autograft transplantation (OAT), Autologous matrix-induced chondrogenesis (AMIC) and autologous chondrocyte implantation (ACI) (From: Andrade et al. Cartilage 2021: 57S-73S).

	OAT	AMIC	ACI
	<b>Magnitude of Change</b>		
KOOS-Total	-	39.8	36.5
KOOS-Pain	-	23.0	23.5
KOOS-Symptoms	-	24.2	21.3
KOOS-ADL	-	23.0	20.2
KOOS-Sports	-	11.0	26.5
KOOS-Quality of Life	-	14.5	29.6
IKDC	27.2	30.1	26.9
Lysholm	27.6	27.0	20.5

## CONCLUSIONS

This single-stage minimally invasive, reparative and reconstructive procedure for trochlear and patellar osteochondral defects demonstrates acceptable early radiographic, clinical and functional scores, and pain relief at most recent follow-up. This procedure is a versatile procedure that targets the deficiencies of the subchondral bone, stabilizing the bone while allowing marrow access, as well as providing a platform for reconstructive or restorative procedures. Further clinical follow-up needs to be attained prior to further conclusions.